

# Midterm Outcomes of Polyvinyl Alcohol Hydrogel Hemiarthroplasty of the First Metatarsophalangeal Joint in Advanced Hallux Rigidus

Foot & Ankle International  
2017, Vol. 38(3) 243–247  
© The Author(s) 2016  
Reprints and permissions:  
sagepub.com/journalsPermissions.nav  
DOI: 10.1177/1071100716679979  
journals.sagepub.com/home/fai

Timothy R. Daniels, MD, FRCSC<sup>1</sup>, Alastair S. E. Younger, MB, ChB, MSc, ChM<sup>2,3</sup>, Murray J. Penner, MD<sup>2</sup>, Kevin J. Wing, MD<sup>2</sup>, Sara Lyn Miniaci-Coxhead, MD<sup>4</sup>, Ellie Pinsker, BA&Sc<sup>1</sup>, and Mark Glazebrook, PhD, MD<sup>5,6</sup>

## Abstract

**Background:** Hallux rigidus is the most common arthritic condition of the foot. A randomized clinical trial of first metatarsophalangeal (MTP) joint hemiarthroplasty with a polyvinyl alcohol (PVA) hydrogel implant (Cartiva) demonstrated pain relief and functional outcomes equivalent to first MTP arthrodesis at 2 years postoperation, with no cases of implant fragmentation, wear, or bone loss. We prospectively determined 5-year outcomes of first MTP hemiarthroplasty with the PVA hydrogel implant.

**Methods:** Patients who underwent first PVA hydrogel MTP hemiarthroplasty in the previously reported trial were evaluated at 5 years postoperatively. Patients underwent physical examination and radiographic evaluation and completed a pain VAS, the Short-Form-36 (SF-36), and the Foot and Ankle Ability Measure (FAAM) sports subscale and activities of daily living (ADL) subscale. At the time of this study, 29 patients had reached 5 years' follow-up. Two were lost to follow-up, leaving 27 patients with mean age 56.1 (range, 40.1–71.9) years. Mean follow-up was 5.4 (range, 4.9–6.4) years.

**Results:** Postoperative active MTP natural joint dorsiflexion and peak MTP dorsiflexion were mean 18.2 (range, 10.0–30.0) and 29.7 (range, 10.0–45.0) degrees, respectively. Pain VAS, SF-36 PCS, FAAM ADL, and FAAM Sports scores demonstrated clinically and statistically significant improvements. Radiographically, no patient demonstrated changes in implant position, implant loosening or subsidence, or implant wear. One implant was removed because of persistent pain and converted to fusion 2 years postoperation.

**Conclusion:** Five years following first MTP hemiarthroplasty with a PVA hydrogel implant, functional outcomes improved significantly, pain was reduced significantly, and the implant demonstrated excellent survivorship.

**Level of Evidence:** Level IV, prospective case series.

**Keywords:** first metatarsophalangeal, hemiarthroplasty, implant, midterm outcomes, polyvinyl hydrogel, survivorship

## Introduction

Hallux rigidus (HR) is the most common arthritic condition of the foot.<sup>17</sup> Its prevalence ranges from 2% to 10% in people aged 20 to 34 years, increasing to 45% in people aged 75 to 79 years.<sup>16</sup> Although a common entity, there is currently no consensus on the optimal operative intervention for this condition.<sup>12,14,17</sup> Historically, the most commonly performed procedure in patients with moderate to severe HR is arthrodesis; however, this procedure leaves the patient with no motion through the first metatarsophalangeal (MTP) joint.<sup>17</sup> Newer techniques have focused on procedures that maintain range of motion (ROM) and allow patients to weight-bear immediately following surgery.

A variety of great toe implants have been developed in an attempt to maintain motion in the setting of HR.

The majority of these implants have failed as a result of loosening, malalignment, dislocation, subsidence, implant

<sup>1</sup>Division of Orthopaedic Surgery, St. Michael's Hospital and University of Toronto, Toronto, Ontario, Canada

<sup>2</sup>Department of Orthopaedics, University of British Columbia, Vancouver, British Columbia, Canada

<sup>3</sup>British Columbia Foot and Ankle Clinic, St. Paul's Hospital, Vancouver, British Columbia, Canada

<sup>4</sup>Cleveland Clinic Foundation, Orthopaedic and Rheumatologic Institute, Cleveland, Ohio, USA

<sup>5</sup>Queen Elizabeth II Health Sciences Center, Halifax, Nova Scotia, Canada

<sup>6</sup>Dalhousie University, Halifax, Nova Scotia, Canada

### Corresponding Author:

Timothy R. Daniels, MD, FRCSC, St. Michael's Hospital, 800-55 Queen Street East, Toronto, Ontario M5C 1R6, Canada.  
Email: danielst@smh.ca

fragmentation, and bone loss.<sup>17,18</sup> In these cases, salvage to arthrodesis is more complicated and results in shortening of the first ray or requires structural bone graft to establish length.<sup>5,7</sup>


A novel polyvinyl alcohol (PVA) hydrogel implant (Cartiva Synthetic Cartilage Implant; Cartiva Inc, Alpharetta, GA) has recently been developed.<sup>18</sup> This synthetic material has a water content comparable to healthy cartilage and a compressive modulus and tensile strength similar to human articular cartilage.<sup>2,13</sup> These biomechanical features make it an ideal material for use in hemiarthroplasty of the first MTP joint.

The efficacy and safety of this small PVA hydrogel implant in comparison to first MTP arthrodesis was recently evaluated in a prospective, randomized, clinical trial conducted at 12 centers in Canada and the United Kingdom. At the 2-year follow-up, the implant hemiarthroplasty demonstrated equivalent pain relief and functional outcomes to first MTP arthrodesis, with no cases of implant fragmentation, wear, or bone loss.<sup>4</sup> The purpose of this prospective study was to determine the mid-term (ie, 5-year) outcomes of patients who underwent PVA hydrogel hemiarthroplasty of the first MTP joint at 3 Canadian centers who participated in the randomized clinical trial.

## Methods

Patients who had undergone first MTP hemiarthroplasty with the PVA hydrogel implant (Cartiva) as part of the previously reported randomized clinical trial<sup>4</sup> were evaluated at least 5 years postoperation. Patients included in this study had been diagnosed with grade II, III, or IV hallux rigidus and received the synthetic implant in the original clinical trial at one of 3 Canadian sites: (1) Queen Elizabeth II Health Sciences Center/Dalhousie University, (2) St. Michael's Hospital/University of Toronto, and (3) St. Paul's Hospital/University of British Columbia. This study was approved prospectively by the Research Ethics Boards at each institution. Sixty-eight patients were enrolled and randomized to receive the PVA hydrogel implant at the 3 Canadian sites included in this study. At the time of this study, 29 patients had reached the 5-year follow-up time point and were therefore eligible for this midterm follow-up study. Two patients were lost to follow-up, leaving 27 patients: 21 females (78%) and 6 males (22%). Their mean age was 56.1 (range, 40.1-71.9) years. Patients had an average body mass index (BMI) of 27.1 (range, 19.2-36.8). The mean time from surgery to follow-up was 5.4 (range, 4.9-6.4) years.

The standardized operative technique used for the synthetic cartilage implant and postoperative care are described elsewhere.<sup>4</sup> At the 5-year evaluation, all patients completed a pain visual analog scale (VAS), the validated Short-Form-36 (SF-36) Health Survey Standard Version 2<sup>6</sup> (a component of



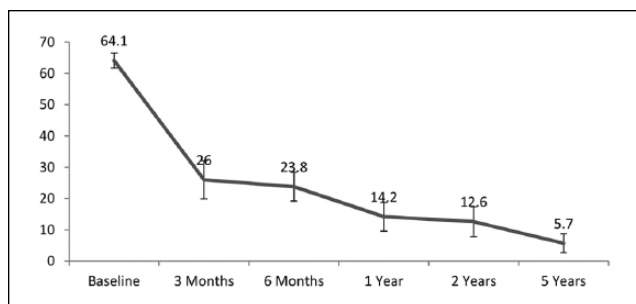
**Figure 1.** Measurement of dorsiflexion.

the American Academy of Orthopaedic Surgeons MODEMS Questionnaire), the validated Foot and Ankle Ability Measure (FAAM) sports subscale and activities of daily living (ADL) subscale<sup>11</sup> with self-reported current level of functioning on a 0-100 percentage point scale, and patient satisfaction questions. The minimal clinically important difference (MCID) determined for the VAS is  $\geq 30\%$  difference,<sup>4</sup> for the SF-36 Physical Component Summary (PCS) score is 2.0 points,<sup>1</sup> for the FAAM sports score is 9 points,<sup>4</sup> and for the FAAM ADL score is 8 points.<sup>4</sup>

Patients also underwent a physical examination and radiographic evaluation. Standing (ie, weight-bearing) anteroposterior and lateral radiographs were evaluated for implant position, residual bone stock, cyst formation, presence or absence of avascular necrosis, device fragmentation, radiolucency, bony reactions, and heterotopic ossification. Active ROM of the first MTP was measured using a goniometer with the patient standing, that is, weight-bearing, as follows: (1) active MTP axial joint alignment (varus/valgus), (2) active MTP natural dorsiflexion (ie, rest position), and (3) active MTP peak (maximum) dorsiflexion (Figure 1).

## Statistical Analysis

Descriptive statistics were generated for demographic and outcome variables, including mean, standard deviation (SD), range, and 95% confidence intervals (95% CIs). Statistical significance was set at  $P \leq .05$  and statistical software (SPSS Statistics, version 23; IBM Corp, Armonk, NY) was used for analyses. Distributions of all variables and scores (overall and subscale) were examined for normality using several methods (histogram, Kolmogorov-Smirnov statistic, skewness, and kurtosis). Based on the small sample size and nonnormal distribution of several variables,



**Figure 2.** Mean VAS Pain scores, from baseline to final follow-up at mean 5.4 (range, 4.9-6.4) years. Error bars represent standard error of the mean. VAS, visual analog scale.

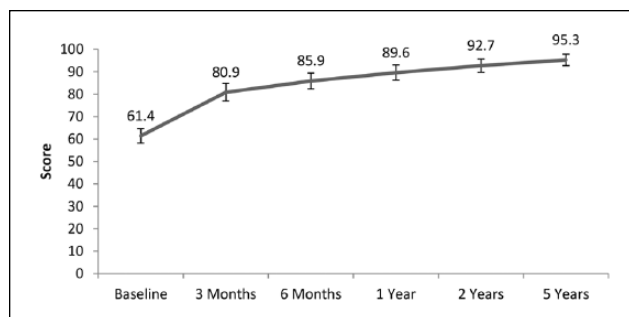
Wilcoxon signed-rank tests were used to compare baseline and postoperative values.

## Results

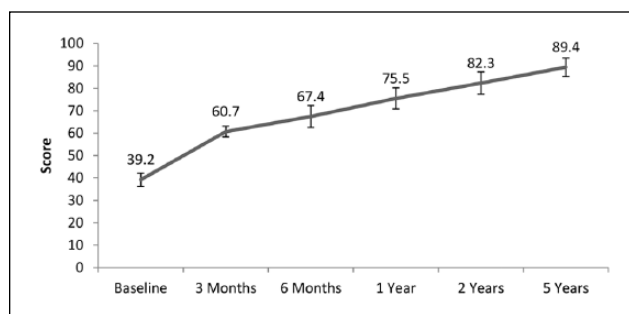
Implant survivorship at 5.4 years was 96%. One implant (4%) was removed from a 47-year-old female with BMI of 34.9 because of persistent pain, and the joint was converted to fusion at 2 years postoperation. Thus, 26 patients with implants were available for evaluation at the 5-year follow-up.

On final examination, active MTP natural joint dorsiflexion was a mean of 18.2 (range, 10.0-30.0) degrees, compared with a mean of 9.4 (range, 0.0-25.0) degrees preoperatively ( $P < .001$ ). Peak MTP dorsiflexion was 29.7 (range, 10.0-45.0) degrees at final follow-up, compared with 20.9 (range, 0.0-50.0) degrees preoperatively ( $P < .02$ ). The postoperative axial MTP joint alignment was 9.3 (range, 0.0-18.0) degrees.

Patient-reported outcome measures demonstrated clinically and statistically significant improvements at 5 years following PVA hydrogel hemiarthroplasty compared with preoperative assessment. The mean pain VAS improved by more than 58 points from baseline to follow-up ( $P < .001$ ) (Figure 2). The mean SF-36 PCS score also improved, from 39.5 (range, 22.0-54.0) points at baseline to 52.2 (range, 25.2-61.6) postoperatively ( $P < .001$ ). With the number of patients in this sample, no significant difference could be detected in SF-36 mental component summary (MCS) scores at baseline (mean 55.6 points; range, 30.7-70.6) compared with follow-up (mean 54.5 points; range, 25.5-62.9;  $P = .29$ ). The mean FAAM ADL subscale score improved by more than 33 points from baseline to final follow-up ( $P < .001$ ) (Figure 3), with a postoperative current level of function of 92.6% (range, 50.0-100.0). The mean FAAM Sports subscale score also improved, by more than 50 points, from baseline to final follow-up ( $P < .001$ ) (Figure 4), with a postoperative current level of function during sports-related activities of 92.3% (range, 50.0-100.0).



**Figure 3.** Mean FAAM Activities of Daily Living (ADL) subscale scores, from baseline to final follow-up at mean 5.4 (range, 4.9-6.4) years. Error bars represent standard error of the mean. FAAM, Foot and Ankle Ability Measure.



**Figure 4.** Mean FAAM Sports subscale scores, from baseline to final follow-up at mean 5.4 (range, 4.9-6.4) years. Error bars represent standard error of the mean. FAAM, Foot and Ankle Ability Measure.

When patients were asked if their overall well-being had improved since surgery, 18 (69%) strongly agreed and 8 (30%) agreed. Seventeen (65%) patients rated their overall level of function as normal, 8 (31%) rated it as nearly normal, and 1 (4%) rated it as abnormal. When asked if patients would undergo the procedure again, 25 (96%) stated they would, whereas 1 (4%) stated they would not.

Radiographs for 23 of 27 patients were available for review at 5-year follow-up. No patient demonstrated changes in implant position. There were no signs of implant loosening or subsidence and no evidence of implant wear. Two patients developed cysts in the proximal phalanx, but none required revision surgery. There were no cases of cyst formation in the metatarsal head. Eight patients developed osteophytes at the first MTP joint, but none required surgery. One patient had the implant removed and was converted to fusion, as described above.

## Discussion

At 5 years following first MTP hemiarthroplasty with a novel PVA hydrogel implant, functional outcomes improved

significantly, pain was reduced significantly, patients were satisfied with the procedure, and the implant demonstrated excellent survivorship.

The efficacy and safety of this implant compared to first MTP arthrodesis at 2 years follow-up were previously demonstrated in a randomized, clinical trial conducted at 12 centers in Canada and the United Kingdom.<sup>4</sup> The various outcome scores recorded at the 2-year follow-up in the previous study were consistently maintained at the 5-year follow-up in the subset of patients from 3 Canadian sites evaluated in the current study. For example, the mean FAAM ADL score was 92.7 (range, 51.2-100.0) and the mean FAAM Sports score was 82.3 (range, 25.0-100.0) at the 2-year follow-up, compared with 95.3 and 89.4, respectively, at the 5-year follow-up.

The PVA hydrogel implant hemiarthroplasty demonstrated no cases of implant fragmentation, wear, or bone loss. The implant had 96% survivorship at 5 years, with only 1 patient requiring a conversion to arthrodesis because of persistent pain. In contrast, early silastic implants had high failure rates as a result of implant loosening, subsidence and fracture, as well as wear debris and bone erosion.<sup>17</sup> Similarly, multiple studies of different metal alloy implants have demonstrated problems with osteolysis, periprosthetic radiolucency, subsidence, loosening, and instability.<sup>17,18</sup> The PVA hydrogel implant is softer than the titanium and cobalt used in metal implants and has a water content and mechanical properties similar to healthy human cartilage.<sup>2,13</sup> It can withstand shear and axial load forces beyond those experienced in the great toe, without fragmentation.

Range of motion through the MTP joint improved following hemiarthroplasty with the PVA hydrogel implant compared with baseline, to an active peak dorsiflexion of 29.7 degrees at 5 years postoperation in our patient cohort. This is also consistent with the mean active peak dorsiflexion of 29 degrees reported for the larger PVA hydrogel hemiarthroplasty cohort in the randomized trial at 2 years postoperation.<sup>4</sup> The maintenance of great toe motion with this procedure is a major benefit for patients.

This study reports clinical outcomes for the first 43% of patients to reach 5 years' follow-up after first MTP hemiarthroplasty with a novel VA hydrogel implant. In approximately 4 years, further follow-up of the entire cohort will provide the 5- to 10-year outcomes for the full patient cohort.

Strengths of this study include the prospective study design and the midterm follow-up of mean 5.4 years. There is a notable paucity of information in the literature, with few reports of outcomes at a mean of 5 or more years following first MTP hemiarthroplasty with an implant.<sup>9,15</sup>

This study has limitations. The size of the cohort is small, but is consistent with other reports of first MTP hemiarthroplasty with various implants.<sup>3,8-10</sup> This study did not compare outcomes to those of patients who underwent

arthrodesis, as midterm survivorship of the implant was the primary outcome. Radiographic follow-up was available for most (85%), but not all, patients. Finally, generalizability of these results is limited, as only the first 43% of patients from the randomized trial were evaluated.

In conclusion, the PVA hydrogel implant decreased pain and improved and maintained function and dorsiflexion 5 years following first MTP hemiarthroplasty. The implant demonstrated excellent survivorship, and overall patients were very satisfied with the procedure and would choose to undergo the procedure again. These results are promising as a viable alternative to fusion of the first MTP joint for management of moderate to severe hallux rigidus.

### Acknowledgments

The authors thank Dagmar Gross for assistance with preparation of this manuscript. The authors would like to acknowledge the contributions of the orthopaedic research assistants at St. Paul's Hospital in Vancouver, British Columbia, St. Michael's Hospital in Toronto, Ontario, and the Queen Elizabeth II Health Sciences Centre in Halifax, Nova Scotia.

### Declaration of Conflicting Interests

The author(s) declared the following potential conflicts of interest with respect to the research, authorship, and/or publication of this article: One or more of the authors has received or will receive benefits for personal or professional use from a commercial party related directly or indirectly to the subject of this article.

Timothy R. Daniels, MD, FRCSC; Alastair S. E. Younger, MB ChB, MSc, ChM; and Mark Glazebrook, PhD, MD, report personal fees from Cartiva, and grants from Cartiva, during the conduct of the study. In addition, Dr. Younger has a patent fastening device for total ankle arthroplasty licensed to him.

### Funding

The author(s) declared receipt of the following financial support for the research, authorship, and/or publication of this article: The authors disclosed receipt of research and institutional support, consulting fees and support for travel expenses from Cartiva Inc for the research, authorship, and/or publication of this article.

### References

1. Angst F, Aeschlimann A, Stucki G. Smallest detectable and minimal clinically important differences of rehabilitation intervention with their implications for required sample sizes using WOMAC and SF-36 quality of life measurement instruments in patients with osteoarthritis of the lower extremities. *Arthritis Rheum.* 2001;45(4):384-391. doi:10.1002/1529-0131(200108)45:4<384::aid-art352>3.0.co;2-0.
2. Baker MI, Walsh SP, Schwartz Z, Boyan BD. A review of polyvinyl alcohol and its uses in cartilage and orthopedic applications. *J Biomed Mater Res B Appl Biomater.* 2012;100(5):1451-1457. doi:10.1002/jbm.b.32694.
3. Bartak V, Popelka S, Hromadka R, Pech J, Jahoda D, Sosna A. ToeFit-Plus system for replacement of the first

- metatarsophalangeal joint [in Czech]. *Acta Chir Orthop Traumatol Cech.* 2010;77(3):222-227.
4. Baumhauer JF, Singh D, Glazebrook M, et al. Prospective, randomized, multi-centered clinical trial assessing safety and efficacy of a synthetic cartilage implant versus first metatarsophalangeal arthrodesis in advanced hallux rigidus. *Foot Ankle Int.* 2016;37(5):457-469. doi:10.1177/1071100716635560.
  5. Bhosale A, Munoruth A, Blundell C, Flowers MJ, Jones S, Davies MB. Complex primary arthrodesis of the first metatarsophalangeal joint after bone loss. *Foot Ankle Int.* 2011;32(10):968-972.
  6. Brazier JE, Harper R, Jones NM, et al. Validating the SF-36 health survey questionnaire: new outcome measure for primary care. *BMJ.* 1992;305(6846):160-164.
  7. Brodsky JW, Ptaszek AJ, Morris SG. Salvage first MTP arthrodesis utilizing ICBG: clinical evaluation and outcome. *Foot Ankle Int.* 2000;21(4):290-296.
  8. Erkocak OF, Senaran H, Altan E, Aydin BK, Acar MA. Short-term functional outcomes of first metatarsophalangeal total joint replacement for hallux rigidus. *Foot Ankle Int.* 2013;34(11):1569-1579. doi:10.1177/1071100713496770.
  9. Heller E, Robinson D. Gelfoam first metatarsophalangeal replacement/interposition arthroplasty—a case series with functional outcomes. *Foot.* 2011;21(3):119-123. doi:10.1016/j.foot.2010.11.007.
  10. Horisberger M, Haeni D, Henninger HB, Valderrabano V, Barg A. Total arthroplasty of the metatarsophalangeal joint of the hallux. *Foot Ankle Int.* 2016;37(7):755-765. doi:10.1177/1071100716637901.
  11. Martin RL, Irrgang JJ, Burdett RG, Conti SF, Van Swearingen JM. Evidence of validity for the Foot and Ankle Ability Measure (FAAM). *Foot Ankle Int.* 2005;26(11):968-983.
  12. McNeil DS, Baumhauer JF, Glazebrook MA. Evidence-based analysis of the efficacy for operative treatment of hallux rigidus. *Foot Ankle Int.* 2013;34(1):15-32. doi:10.1177/1071100712460220.
  13. Noguchi T, Yamamuro T, Oka M, et al. Poly(vinyl alcohol) hydrogel as an artificial articular cartilage: evaluation of biocompatibility. *J Applied Biomater.* 1991;2(2):101-107.
  14. Simpson GA, Hembree WC, Miller SD, Hyer CF, Berlet GC. Surgical strategies: hallux rigidus surgical techniques. *Foot Ankle Int.* 2011;32(12):1175-1186. doi:10.3113/FAI.2011.1175.
  15. van Duijvenbode DC, Bulstra GH, Nijssse BA. Nineteen-year follow-up of the silastic double stemmed hinge prosthesis of the first metatarsophalangeal joint. *Foot Ankle Surg.* 2013;19(1):27-30. doi:10.1016/j.fas.2012.08.001.
  16. van Saase JL, van Romunde LK, Cats A, Vandenbroucke JP, Valkenburg HA. Epidemiology of osteoarthritis: Zoetermeer survey. Comparison of radiological osteoarthritis in a Dutch population with that in 10 other populations. *Ann Rheum Dis.* 1989;48(4):271-280.
  17. Yee G, Lau J. Current concepts review: hallux rigidus. *Foot Ankle Int.* 2008;29(6):637-646. doi:10.3113/FAI.2008.0637.
  18. Younger ASE, Baumhauer JF. Polyvinyl alcohol hydrogel hemiarthroplasty of the great toe: technique and indications. *Techn Foot Ankle Surg.* 2013;12(3):164-169.